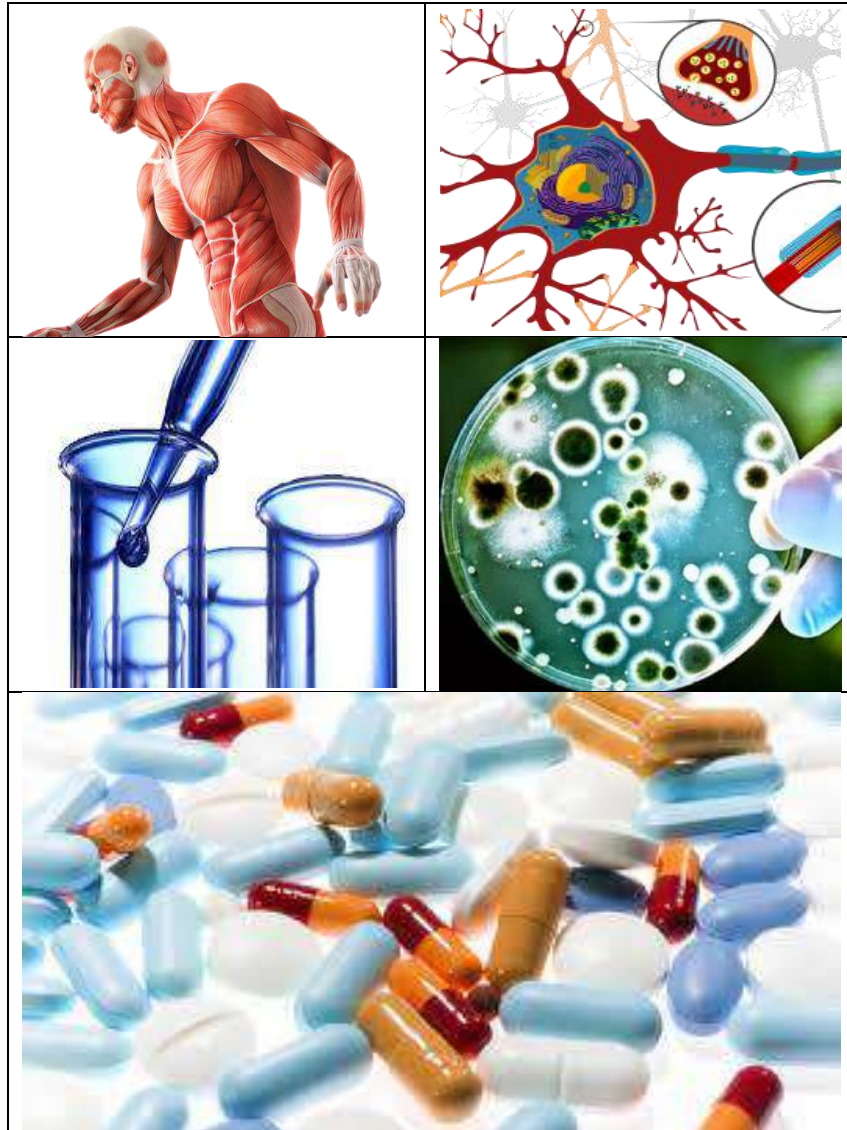


**Musculoskeletal Module**  
**First Professional Year MBBS**  
**8 Weeks**



## Introduction to Module

Musculoskeletal system Module is designed to provide guidance on introduction to the basics of human musculoskeletal system. Moreover, the module is aligned to the general outcomes required at the exit level, and includes introductory sessions on preventive medicine, communication skills, professionalism, self- management, and developing scholarly skills. The module committee will facilitate the students with any issues that they have, while settling down in the new environment. You will also learn the skills required for practical implications in the field of medicine. Moreover, working within teams will enhance your co-operative and approachable working style

### GENERAL LEARNING OUTCOMES

By the end of this module the students should be able to;

#### Knowledge

By the end of this module, students should be able to:

1. Develop an understanding of the fundamental components of the musculoskeletal system.
2. Explain the structure & function of the musculoskeletal (MSK) components of limbs and back.
3. Describe how injury and disease alter the MSK structure & function.
4. Integrate concepts relating to various metabolic processes, their disorders and relevant lab investigations in the study of human MSK system.
5. Describe the role of the limbs (upper/lower) in musculoskeletal support, stability and movements.
6. Describe the development of the limbs & correlate it with organization and gross congenital anomalies of the limbs.
7. Identify the anatomical features of bones, muscles & neurovascular components of the limbs and correlate them with their functions, injuries and clinical problems.
8. Describe the types, formation, stability, function & clinical significance of joints of the upper and lower limb.
9. Describe the basic histology of muscle fibers including its molecular structure (Sarcomere).
10. Explain the mechanism of excitation and contraction of skeletal and smooth muscles.
11. Describe the basis for the use of therapeutic agents to modulate neuromuscular transmission.
12. Describe the general principles of MSK pain management.
13. Describe ergonomics and its principles. Prevention of different MSK disorders.
14. Interpret the mechanism of post-mortem rigidity. (spiral II)
15. Give an overview of pathology of bones, muscles and joints.

16. Explain the role of different minerals, hormones and specific metabolic products related to the musculoskeletal system and correlate them with their relevant clinical metabolic disorders.
17. Interpret the relevant laboratory investigations for diagnosis of common musculoskeletal disorders. (Spiral two)
18. To develop the critical thinking and analysis in the context of various case scenarios pertaining to locomotors system.

### **Skills**

By the end of this module, it is a core objective that students should have acquired the following skills:

1. Demonstrate the anatomical structures of the limbs in a dissected cadaver/Model/prosecuted specimen & X-ray.
2. Demonstrate the provision of first aid measures in case of a limb fracture.
3. Communicate effectively in a team with colleagues and teachers.

### **Attitude**

While not necessarily taught explicitly, students are expected to develop following attitudes throughout the course:

1. Demonstrate respect and care for the cadaver and prosected parts.
2. Demonstrate humbleness and use socially acceptable language during academic and social interactions with colleagues and teachers.
3. Make ethically competent decisions when confronted with an ethical, social or moral problem related to MSKS in professional or personal life.
4. Discuss ethical issues social and preventive aspect of health care in the context of MSK system.
5. To create awareness about the ethical, social and preventive aspect of health care in the context of locomotor system.

## THEMES FOR MUSCULOSKELETAL MODULE

SNO	Theme	Duration
1	Orientation and shoulder pain	2 weeks
2	Weak grip and painful hand	1 week
3	Pain lower limb/limping	2 weeks
4	Bony arches and fracture of foot	1 week
5	Backache	1 week
6	Muscle weakness and fatigue	1 week

**Musculoskeletal  
MODULE**

**THEME -I**

**ORIENTATION AND  
SHOULDER PAIN**

SNO.	Topic	Learning Outcomes
<b>ANATOMY</b>		
1	Introduction	<ul style="list-style-type: none"> <li>• Define osseous tissue</li> <li>• Classify the skeletal system (axial and appendicular)</li> <li>• Name and locate different bones of axial and appendicular skeleton</li> <li>• Classify bones</li> <li>• Describe general features of bones</li> <li>• Describe Nerve/blood supply of bone</li> <li>• Describe bone marrow and its types</li> <li>• Describe ossification and its types</li> <li>• Describe surface markings of bones</li> <li>• Define fracture, osteoporosis, rickets, osteomalacia</li> <li>• Introduction to muscular system</li> <li>• Classify the muscles according to the directions of fibers</li> <li>• Classify the skeletal muscles according to their action.</li> <li>• Types of skeletal muscle fibers(Type1 ,2,3)</li> <li>• Describe the nomenclature of skeletal muscles</li> <li>• Describe the principle of innervations and nerve supply of muscles</li> <li>• Define paralysis, hyperplasia, hypertrophy, myasthenia gravis</li> </ul>
2	Introduction to locomotion and upper limb	<p>Identify the extent of the upper limb.</p> <p>Identify various regions of upper limb.</p> <p>Describe the division of the regions into compartments.</p> <p>State the contents of compartments of arm, forearm &amp; hand</p> <p>Describe the joints of upper limb.</p> <p>Describe the clinical anatomy of upper limb</p>

3	Osteology of clavicle	<p>Recognize the bone</p> <p>Identify the site of bone</p> <p>State the bony land marks of clavicle: like borders, surfaces &amp; land mark used for bone determination</p> <p>Describe &amp; demonstrate the attachments of muscles.</p> <p>Describe the common fractures of the bone.</p> <p>Identify and describe the salient features of the bones scapula and clavicle</p> <p>Describe the surface anatomy clavicle</p> <p>Describe the radiological anatomy clavicle</p> <p>Describe the applied anatomy clavicle</p>
4	Osteology of scapula	<p>Recognize the bone.</p> <p>Identify the site of bone.</p> <p>State the bony landmarks of scapula: like borders, surfaces &amp; land mark used for bone determination.</p> <p>Demonstrate the attachment of muscles on scapula</p> <p>Describe the common fractures of the bone.</p> <p>Identify and describe the salient features of the bones scapula.</p> <p>Identify the attachments to scapula</p> <p>Describe the surface anatomy scapula</p> <p>Describe the radiological anatomy scapula.</p> <p>Describe the applied anatomy scapula.</p>

5	Osteology of humerus	<p>Recognize the bone.</p> <p>Identify the site of bone.</p> <p>State the bony landmarks of humerus: like borders, surfaces &amp; land mark used for bone determination.</p> <p>Demonstrate the attachment of muscles &amp; ligaments.</p> <p>Describe the common fractures of the bone.</p> <p>Identify and describe the salient features of the humerus</p> <p>Identify the attachments to humerus</p> <p>Describe the surface anatomy humerus</p> <p>Describe the radiological anatomy humerus</p> <p>Describe the applied anatomy humerus</p>
6	Muscles of the pectoral girdle	<p>Recognize the role of muscles of pectoral region in stabilizing the pectoral girdle.</p> <p>List the muscle of pectoral girdle.</p> <p>Describe &amp; Demonstrate the attachments of muscle of pectoral girdle, nerve supply and actions.</p> <p>Describe the structural organization of the clavi-pectoral fascia.</p> <p>Identify the triangle of auscultation.</p> <p>Describe the nerves and blood vessels of this region</p>
7	Muscles of the shoulder region	<p>Recognize the extent of shoulder region.</p> <p>Describe the muscle of shoulder region.</p> <p>List the muscles of shoulder region.</p> <p>State the detailed structures of each muscle with respect to Origin, Insertion, Nerve supply and Action of muscles with any characteristic features.</p>
8	The shoulder joint & its movements	<p>Classify the type of shoulder joint.</p> <p>Describe the structure of shoulder joint.</p>



		<p>Name the muscles acting on the joint/rotator cuff muscles.</p> <p>Explain the range of mobility.</p> <p>Describe the movements of shoulder joint.</p> <p>Explain the clinical anatomy of the joint</p>
9	Brachial plexus	<p>Mention the formation of brachial plexus (roots, trunk, division, and cords).</p> <p>Describe the relation of brachial plexus also in connection to clavicle (Supra, retro, infra clavicular parts).</p> <p>State the branches arising the different cords.</p> <p>Draw the brachial plexus.</p> <p>Describe the clinical correlates of the brachial plexus.  Erb duchane palsy  Klumpke palsy  Saturday night palsy</p>
10	Nerves of upper limb	<p>Describe the course and branches of nerves of upper limbs.  Axillary nerve  Musculocutaneous nerve  Radial Nerve  Ulnar Nerve  Median Nerve</p> <p>Explain the injuries associated with these nerves.</p> <p>Identify the causes and motor and sensory loss associated with nerve injuries of upper limb.</p> <p>Apply knowledge of gross anatomy to identify the deformities associated with these nerves.</p>
	Axilla	<p>Describe the position, shape of axilla.</p> <p>Describe the boundaries and content of axilla</p> <p>Describe the boundaries and muscle forming the boundaries of axilla.</p> <p>Describe the formation, course and relations of axillary vessels.</p> <p>Describe arrangement and groups axillary lymph nod</p>
11	Arm	<p>Describe the compartments of arm and how they are formed.</p>

		<p>Identify and explain the muscles and their actions found in the arm.</p> <p>Describe the nerve supply of arm.</p> <p>Describe the course of the nerves</p> <p>Identify the branches of the nerves</p> <p>Relate &amp; integrate with the clinical correlations</p> <p>Describe cutaneous supply of arm.</p>
12	Brachial vessels	<p>Describe the extension, relation and branches of the Brachial artery.</p> <p>Describe the course of the Basilic and cephalic veins</p> <p>Describe and explain the formation and purpose of the scapular anastomosis.</p>
13	Elbow joint	<p>Identify the type of the joint.</p> <p>State and Identify the muscles acting on the elbow joint.</p> <p>Describe the neurovascular supply of the joint.</p> <p>Describe the carrying angle and applied aspect of the joint.</p> <p>Describe the anastomosis and collateral circulation.</p> <p>Describe formation of anastomosis around elbow joint</p>
14	Osteology of ulna	<p>Recognize the bone.</p> <p>Determine the side of bone.</p> <p>Identify the features of bone.</p> <p>Identify the muscles attached to bone.</p> <p>Describe the common fractures of the bone.</p> <p>Describe and Identify the salient features of the ulna</p> <p>Identify the attachments to ulna</p> <p>Describe the surface anatomy ulna and the radiological anatomy ulna</p>

		Describe the applied anatomy ulna
15	Superficial veins, lymphatic's and lymph nodes of upper limb	<p>Describe the normal anatomy of veins of upper limb.</p> <p>Differentiate between superficial and deep veins.</p> <p>Describe the features of individual superficial veins of upper limb.</p> <p>Correlate the applied anatomy with the gross anatomy of superficial Veins of upper limb.</p> <p>Describe the structure of a lymph node.</p> <p>Identify the groups of lymph nodes.</p> <p>Describe groups and area of drainage of each group of lymph nodes.</p> <p>Describe the commencement, course and termination of superficial lymphatic vessels.</p> <p>Describe the clinical conditions related to lymphatic channels of upper</p>
16	Cubital fossa	<p>Describe the boundaries, the contents and the relationship among structures of Cubital fossa.</p> <p>Demonstrate the surface anatomy of the Cubital fossa.</p> <p>Explain the clinical importance of the Cubital fossa.</p>
17	Anterior compartment of forearm	<p>List the muscles of forearm.</p> <p>State the nerve supply of these muscles.</p> <p>Explain actions of the muscles of anterior compartment of forearm.</p> <p>Describe attachment and functions of flexor retinaculum</p> <p>Identify/Describe muscles of the anterior compartment of the arm (origin, insertion, nerve supply, blood supply, and action)</p>
18	Posterior compartment of forearm	<p>Explain the organization of muscles of posterior compartment of forearm</p> <p>Identify/Describe muscles of the posterior compartment of the arm (origin, insertion, nerve supply, blood supply, and action)</p> <p>State the nerve supply of these muscles.</p>

		<p>Explain the actions of the muscles of posterior compartment of forearm.</p> <p>Describe the structural organization of the Extensor Retinaculum</p>
19	Blood vessels & nerves of the forearm	<p>Describe the different vessels &amp; nerves in forearm.</p> <p>Describe the location, destination, course &amp; relations of radial and ulnar arteries &amp; their branches in forearm.</p> <p>Describe the deep veins of forearm and their tributaries.</p> <p>Describe the location, destination, course &amp; relations of ulnar, radial and median nerves &amp; their branch.</p>
20	Radio-ulnar joint	<p>Recognize the details of Radio-ulnar joint.</p> <p>Describe and explain the movements occurring on Radio-ulnar joint.</p> <p>Name the muscles acting in pronation and supination.</p> <p>Describe the nerve supply and blood supply of Radio-ulnar joint.</p> <p>Describe clinical problems related to Radio-ulnar joints.</p>
21	Surface anatomy of upper limb	Demonstrate the surface markings for various arteries of upper limb
<b>Embryology</b>		
22	Somitogenesis	<p>Define the process of gastrulation.</p> <p>Describe the development of mesoderm.</p> <p>Describe the process of somitogenesis.</p> <p>Describe the formation of cartilage</p>
23	Development of bone, cartilage and joints	<p>Describe histogenesis of Bone</p> <p>Describe the Intramembranous Ossification</p> <p>Describe the Endochondral Ossification</p> <p>Describe the Ossification of limb bones</p> <p>Describe the development of joints</p> <p>Describe the development of cartilage</p> <p>Describe developmental events of fibrous joints</p>

		<p>Describe developmental events of cartilaginous joint</p> <p>Describe developmental events of synovial joints</p> <p>Describe important congenital correlates</p>
24	Development of upper limb	<p>Describe the early stages of upper limb development</p> <p>Describe the development of upper limb buds</p> <p>Describe the final stages of upper limb development</p> <p>Describe and explain the anomalies of the upper limb</p>
25	Development of muscles	<p>Describe the development of skeletal muscle.</p> <p>Describe the development of Myotomes and derivatives of epaxial divisions of myotomes and derivatives of hypaxial divisions of myotomes</p>
<b>HISTOLOGY</b>		
26	Bone histology	<p>Define and identify compact and spongy bone</p> <p>Describe and identify bone matrix (organic and inorganic component)</p> <p>Describe and identify cells of boney tissue i.e. (osteoprogenitor, osteoblasts, osteoclast, and osteocytes)</p> <p>Describe and identify periosteum and endosteum</p> <p>Describe and identify the microscopic structure of bone i.e. (primary bone, secondary bone and haversian system)</p> <p>Describe Functions of various bone cells</p> <p>Describe important Functions and its role in calcium metabolism</p>
27	Classification & histology of cartilage	<p>Describe the General properties of cartilage</p> <p>Describe the Different types of cartilage</p> <p>Describe the Hyaline, Elastic and Fibrocartilage</p> <p>Explain the growth of cartilage</p>
28	Histology of cartilage	<p>Identify types of cartilages on microscopy, including distinctive features of each.</p>

		<p>Describe the structural basis.</p> <p>Classify and distinguish three types of cartilages</p> <p>Describe the microscopic structure of hyaline cartilage</p> <p>Describe the microscopic structure of Elastic cartilage</p> <p>Describe the microscopic structure of fibrous cartilage</p> <p>Describe important functional correlates of three types of cartilages</p>
29	Classification & histology of bone	<p>Recognize bone and its functions and composition.</p> <p>Differentiate between woven bone and lamellar bone.</p> <p>Differentiate between compact bone and spongy bone.</p> <p>Describe the applied aspect of bone</p>
30	Histology of bone	<p>Identify three types of bone on microscopy, including distinctive features of each.</p> <p>Describe the structural basis of classification.</p>
31	Histology of muscles	<p>Identify three types of muscles on microscopy, including distinctive features of each muscle fiber.</p> <p>Describe the structural basis of muscle striations.</p> <p>Recognize the structural elements that produces muscle contraction and brings the movement of a body part.</p> <p>Recognize the function and organization of the connective tissue in muscle.</p> <p>Classify and distinguish three types of muscles</p> <p>Describe the microscopic structure of skeletal muscle</p> <p>Describe important functional correlates of skeletal, smooth</p> <p>Describe the microscopic structure of smooth muscle</p> <p>Identify/Describe the microscopic structure of cardiac muscle fiber</p> <p>Describe important functional correlates of cardiac muscle fiber</p>

<b>Physiology</b>		
32	Skeletal vs smooth muscle	Differentiate between skeletal muscle and smooth muscle.
33	Mechanism of muscle contraction	Describe the general mechanism of muscle contraction. Describe the molecular mechanism of muscle contraction
34	Energetics of muscle contraction	Describe the energetics of muscle contraction.
35	Terms related to MSK	Describe the following terms related to MSK Excitable tissue  Stimulus  Threshold  Depolarization  Hyperpolarization  Presynaptic potential  Post synaptic potential  Goldmann Equation  Nernst Equation
<b>Biochemistry</b>		
36	Connective tissues	Explain in detail the biochemistry of connective tissues.
37	Glycosaminoglycan	Discuss the role of glycosaminoglycan (GAG) in the formation of the connective tissues, cartilage, skin, blood vessels and tendons
38	Collagen	Describe the chemical structures of cellular matrix of collagen and elastin
39	Chemistry of Amino acids and Proteins	<ul style="list-style-type: none"> <li>- Describe structure of amino acids &amp; Proteins</li> <li>- Classify proteins</li> <li>- Describe different types of Plasma proteins</li> </ul>
<b>Biochemistry Practical</b>		
40	Detection of Sulphur containing amino acids	Define Sulphur containing amino acids their structure and types  Lead Sulphate test

**Musculoskeletal  
MODULE**

**THEME -II**

**Weak grip and painful  
hand**





SNO.	Topic	Learning Outcomes
<b>ANATOMY</b>		
1	Osteology of radius & hand	<p>Recognize the bones of forearm &amp; hand</p> <p>Determine side of bones.</p> <p>Identify the features of bones.</p> <p>Identify the muscles attached to bones.</p> <p>Describe the ossification of bones</p> <p>Explain the clinical significance of bones.</p> <p>Describe the common fractures of the bone.</p> <p>Describe and Identify the salient features of the radius</p> <p>Identify the attachments to radius</p> <p>Describe the surface anatomy radius and the radiological anatomy radius</p> <p>Describe the applied anatomy radius</p> <p>Describe and Identify the salient features bones of hand</p> <p>Identify the attachments to bones of hand</p> <p>Describe the surface anatomy main bones of hand and the radiological anatomy of main bones</p> <ul style="list-style-type: none"> <li>• Describe the applied anatomy main bones of hand including carpal tunnel and fractures</li> </ul>
2	Muscles of hand	<p>Recall the structure and functions of palmar aponeurosis.</p> <p>Describe the attachments, nerve supply &amp; actions of muscles of hand.</p>

		<p>Describe the thenar Muscles.</p> <p>Correlate the movements of thumb with hand anatomy.</p> <p>Identify the anatomical snuffbox.</p> <p>Relate applied with gross anatomy of few structures of hand</p> <p>Enumerate, describe and identify the small muscles of the hand</p> <p>Describe Surface anatomy of important muscles of hand</p> <p>Identify structures on transverse MRI hand taken at various levels</p> <p>Describe relevant clinical anatomy of important muscles</p> <p>Identify/Describe joints of the hand and fingers (intercarpal joints, carpometacarpal and intermetacarpal joints, carpometacarpal joint of the thumb, and metacarpophalangeal joints</p> <p>Describe surface , radiological and clinical anatomy of important joints</p>
3	Vessels & nerves of the hand	<p>Identify different vessels in hand.</p> <p>Describe the location, destination course relations of radial and ulnar arteries in hand.</p> <p>State the branches of radial and ulnar arteries in hand.</p> <p>Describe the formation of superficial and deep palmar arch, veins of hand and their tributaries.</p> <p>Describe the nervous supply of the hand.</p>
4	Wrist joint	<p>Recognize the details of wrist joints.</p> <p>Describe and explain the movements occurring on wrist joints.</p>

		<p>Name the muscles acting in pronation and supination.</p> <p>Describe the nerve supply and blood supply of wrist joints.</p> <p>Describe wrist joint, nerve supply and blood supply. Describe clinical problems related to Wrist joints.</p>
5	Spaces of the palm	<p>Identify the different spaces of the hand on both palmar and dorsal aspects.</p> <p>Describe the clinical importance of these spaces</p>
<b>Physiology</b>		
10	Describe the important terms	<p>Describe the following</p> <ul style="list-style-type: none"> <li>Motor unit</li> <li>Summation</li> <li>Tetanization</li> <li>Staircase effect</li> <li>Skeletal muscle tone</li> <li>Muscle fatigue</li> <li>Agonist</li> <li>Antagonists</li> <li>Coactivation of agonist and antagonis</li> </ul>
11	Excitation contraction coupling in skeletal muscles	<p>Discuss the process of excitation contraction coupling in skeletal muscles.</p> <p>Explain Transverse tubule-sarcoplasmic reticulum system</p> <p>Describe Release of Calcium ions by sarcoplasmic reticulum</p> <p>Explain Role of Calcium pump</p> <p>Describe Excitatory pulse of Ca<sup>+</sup></p>
12	Muscle action potential	Describe the muscle action potential.
13	Excitation contraction coupling	Describe excitation contraction coupling of skeletal muscle.
<b>BIOCHEMISTRY</b>		
14	Role of calcium and phosphorus	Explain the role of calcium and phosphorous in formation of cellular matrix and bone
15	Vitamins	<p>Vitamins and their role</p> <p>Define vitamins</p> <p>Classify vitamins</p> <p>Differentiate between Fats and water soluble vitamins</p> <p>Describe role of Vitamin A</p> <p>Explain the role of Vitamin D</p> <p>Describe the role of Vitamin E</p>

		Describe the role of water soluble vitamins
16	Introduction to minerals	Define Minerals, Define major and minor minerals Describe classification of minerals
<b>Biochemistry Practical's</b>		
17	Detection of Cyclic amino Acids	Define Cyclic amino Acids Understand their structure and types Xanthoproteic Test

# **Musculoskeletal MODULE**

## **THEME -III**

**Pain lower limb/limping**

SNO	Topic	Learning Outcome
1	Introduction to lower limb	<p>Recognize different parts of lower limb.</p> <p>Describe regions of lower limb.</p> <p>List the bones of lower limb.</p> <p>Describe the vessels and nerves of lower limb.</p> <p>Identify different land marks in different regions of lower limb</p>
2	Hip bone	<p>Identify the different parts of the bone.</p> <p>Describe side determination.</p> <p>Describe muscle attachments.</p> <p>Describe ligamentous attachments.</p> <p>Describe the different bones articulating with the hip bone</p> <p>Identify the different parts of the bone.</p> <p>Describe the common fractures of the bone.</p> <p>Identify and describe the salient features of the bones of hip bone</p> <p>Identify the attachments of hip bone</p> <p>Describe the surface anatomy of hip bone</p> <p>Describe the radiological anatomy of hip bone</p> <p>Describe the applied anatomy of hip bone.</p>
3	The hip joint and movements	<p>Describe the characteristics features of synovial joint</p> <p>Describe the Articular surfaces of hip joint</p> <p>Identify the capsule of hip joint</p> <p>Describe the synovial membrane, cavity &amp; fluid of hip joint</p>

		<p>Enumerate the ligaments of hip joint &amp; describe their attachments</p> <p>Describe the movements possible at hip joint</p> <p>Describe the clinical correlates of the hip joint</p> <p>Describe surface and radiological anatomy (X-rays and MRI) and clinical of hip joints</p>
4	Gluteal region	<p>Describe the boundaries of gluteal region</p> <p>Describe bones and ligaments of gluteal region</p> <p>Describe the different structures entering and leaving gluteal region</p> <p>Describe muscles of the gluteal region.</p> <p>Describe Vessels of the gluteal region.</p> <p>Describe nerves of the gluteal region.</p> <p>Describe about certain clinical correlates regarding gluteal region</p> <p>Describe Surface anatomy of important muscles</p> <p>Identify structures on transverse MRI of gluteal region taken at various levels</p> <p>Describe clinical anatomy of important muscles</p>
5	Femur	<p>Identify different parts of the femur</p> <p>Determine the side of the bone</p> <p>Identify the surfaces and borders of the bone</p> <p>Describe the common fractures of the bone.</p> <p>Describe the attachments of the different muscles and ligaments on the bone</p>



		<p><b>Describe the arterial supply of the bone</b></p> <p><b>Relate to the general idea about fractures of femur and other clinical conditions Identify and describe the salient features of the bones of hip bone</b></p> <p><b>Describe the surface anatomy of femur</b></p> <p><b>Describe the radiological anatomy of femur</b></p> <p><b>Describe the applied anatomy of femur</b></p>
6	Nerves of lower limb and their injuries	<p>Identify the names of nerves and their main branches innervating lower limb</p> <p>Identify the nerves closely related to a bone or other structure of lower limb</p> <p>Recognize the main nerves commonly vulnerable to injury</p> <p>Identify the main area and loss of function if particular nerve is injured</p> <p>Define and understand terms neuritis, anesthesia, par aesthesia, paralysis, neuralgia, sciatica</p>
7	Superficial vessels and lymphatic's of lower limb	<p>Enumerate and describe the superficial arteries of lower limb</p> <p>Name and Describe superficial veins of lower limb</p> <ul style="list-style-type: none"> <li>List and Describe the superficial lymphatic vessels and lymph nodes of lower limb</li> </ul>
8	Deep fascia of thigh, iliotibialtract and superficial vessels	<p>Describe the arrangement of deep fascia in thigh</p> <p>Describe how the iliotibial tract participates in walking and running</p> <p>Describe the location of saphenous opening and its relations</p> <p>Describe the great saphenous vein.</p> <ul style="list-style-type: none"> <li>Describe clinical correlates of saphenous vein</li> </ul>

9	Muscles of the anterior fascial compartment of thigh	<p>Describe the muscles of anterior compartment of thigh.</p> <p>Describe the nerve supply of anterior Compartment.</p> <ul style="list-style-type: none"> <li>Describe the action of these muscles</li> </ul>
10	Nerves and vessels of anterior compartment of thigh	<p>Describe the nerve supply of the anterior compartment of thigh.</p> <p>Describe the blood supply and the venous drainage of anterior compartment of thigh</p> <ul style="list-style-type: none"> <li>Describe the action of these muscles</li> </ul>
11	The medial compartment of thigh	<p>Describe the muscles of medial compartment of the thigh.</p> <p>Describe the nerve supply of these muscles.</p> <p>Describe the actions of the muscles of medial compartment of thigh</p> <ul style="list-style-type: none"> <li>Describe the vessels of medial compartment of the thigh</li> </ul>
12	Posterior compartment of thigh	<p>Describe the muscles of posterior compartment of thigh</p> <p>Describe the arterial supply of posterior compartment of thigh</p> <p>Discuss the trochanteric and cruciate anastomosis at the back of thigh</p> <p>Describe the venous drainage of this region</p> <p>Describe the nerve supply of posterior compartment of thigh and</p> <ul style="list-style-type: none"> <li>Relate to the clinical conditions effecting the region</li> </ul>
13	Popliteal fossa	<p>Describe the boundaries of popliteal fossa.</p> <p>Describe the contents of the popliteal fossa.</p> <ul style="list-style-type: none"> <li>Describe some clinical correlates regarding popliteal fossa</li> </ul>

14	Femoral triangle and its contents	<p>Describe the boundaries of femoral triangle</p> <p>List the contents of femoral triangle</p> <p>Describe the femoral sheath &amp; canal</p> <p>Describe the clinical correlates of the Femoral triangle.</p> <ul style="list-style-type: none"> <li>Describe the location, boundaries and contents of adductor canal</li> </ul>
15	Tibia bone	<p>Describe the division of tibia bone in 3 parts</p> <p>Identify the surfaces and borders of tibia</p> <p>Describe the attachments of muscles on the tibia bone</p> <p>Describe the ossification of tibia and its primary and secondary ossification centers</p> <p>Describe the common fractures of the bone.</p> <p>Identify and describe the salient features of the bone of leg</p> <p>Identify the attachments to the bone of the leg</p> <p>Describe the surface anatomy of leg</p> <p>Describe the radiological anatomy of leg</p> <ul style="list-style-type: none"> <li>Describe the applied anatomy of leg</li> </ul>
16	Fibula & bones of foot	<p>Determine the side of bone.</p> <p>Describe the bony features along with its different attachments on the fibula.</p> <p>Name and describe the tarsal bones and their arrangement</p>

		<p>Name and describe the metatarsal bones and phalangeal bones.</p> <p>Describe the common fractures of the bone.</p> <p>Describe the muscles of the sole of the foot (origin, insertion, nerve supply, blood supply, and action)</p> <p>Describe the muscles of the dorsum of the foot (origin, insertion, nerve supply, blood supply, and action)</p> <p>Describe Surface anatomy of important muscles</p> <p>Identify structures on transverse MRI of foot taken at various levels</p> <p>Describe clinical anatomy of important muscles</p>
17	Anterior and lateral compartment of leg	<p>identify the boundaries of the compartments of leg</p> <p>State the muscles of anterior and lateral compartment of leg</p> <p>Describe the vessels of anterior and lateral compartment of leg</p> <p>Describe the nerves of lateral and anterior compartment of leg</p> <ul style="list-style-type: none"> <li>• Describe action of these muscles</li> </ul>
18	Posterior compartment of leg	<p>Explain the muscles of posterior Compartment of leg.</p> <p>Describe nerve supply of these muscles.</p> <p>Explain the actions of the muscles of</p> <ul style="list-style-type: none"> <li>• posterior compartment of leg</li> </ul>
19	Knee joint	<p>Describe the type of knee joint</p> <p>Describe the articular surfaces of this joint</p> <p>Describe the articular capsule</p> <p>Describe the synovial membrane and the synovial cavity</p>

		<p>Enumerate the ligaments of knee joint</p> <p>Describe the bursa around the knee joint</p> <p>Describe the blood and nerve supply of the knee joint</p> <p>Describe the mechanism of locking and unlocking of knee joint.</p> <p>Describe surface and radiological anatomy (Xrays and MRI) and clinical</p> <ul style="list-style-type: none"> <li>• of knee joints</li> </ul>
20	Surface anatomy of lower limb	<p>Demonstrate the surface anatomy of arteries of lower limb.</p> <p>Demonstrate the surface anatomy of superficial &amp; deep veins lower limb.</p> <p>Demonstrate the surface anatomy of nerves of lower limb</p>
<b>Embryology</b>		
21	Development of lower limb	<p>Describe the early stages of lower limb development</p> <p>Describe the development of lower limb buds</p> <p>Describe the final stages of lower limb development</p> <p>Describe and explain the anomalies of the lower limb</p>
<b>Biochemistry</b>		
22	Sodium, potassium and chlorine in biology	<p>Discuss RDA, serum Levels</p> <p>Enlist sources of Sodium, Potassium and chlorine, Describe functions</p> <p>Discuss absorption excretion, Describe disorders related to increase and decrease in amount of Sodium, Potassium and chlorine</p>
<b>Biochemistry Practical's</b>		
23	Salt Saturation Test	Perform Salt Saturation Test



# **Musculoskeletal MODULE**

## **THEME -IV**

**Bony arches and fracture of  
foot**

SNO	Topic	Learning Outcome
<b>ANATOMY</b>		
1	Muscles and neurovascular supply of the foot	<p>Describe the dorsal muscles of foot.</p> <p>Describe the origin and insertion of planter muscles of foot.</p> <p>Describe their nerve supply and actions.</p> <p>Describe vascular and nervous supply of sole and dorsum of foot</p> <p>Describe their course through foot</p> <p>Describe relationships</p> <p>Identify and describe the salient features of the bone of foot</p> <p>Identify the attachments to the bone of the foot</p> <p>Describe the surface anatomy of foot</p> <p>Describe the radiological anatomy of foot</p> <p>Describe the applied anatomy of foot</p>
2	Arches of foot	<p>Describe the arches of foot</p> <p>Describe the factors responsible for their maintenance of the arches of the foot</p> <p>Recognize the injury when it occurs and be able to evaluate plantar fasciitis.</p> <p>Describe about counselling regarding the rehabilitation for plantar fasciitis</p>
<b>Biochemistry</b>		
3	Role of vitamin c & D	Describe the role of Vitamin C and Vitamin D in the formation of connective tissues and bones.
4	Iodine in Biology	<p>Discuss RDA, serum Levels Iodine</p> <p>Enlist sources of</p> <p>Describe functions</p> <p>Discuss absorption excretion,</p>



		Describe disorders related to increase and decrease in amount of Iodine
<b>PATHOLOGY</b>		
5	introduction to Bone pathology	Define and differentiate osteopenia, osteoporosis, osteomalacia  Define osteomyelitis  Enlist various forms of arthritis
Forensic Medicine		
6	Injury	Define injury on medico legal basis. Classify injury. Define mechanical injury Classify mechanical injury Describe mechanisms of injury. Interpret the nature (manner) of injury.
7	Wound	Define wound. Define hurt. Identify factors affecting appearance of wound



**Musculoskeletal  
MODULE**

**THEME -V**

**Backache**

SNO	Topic	Learning Outcome
<b>ANATOMY</b>		
1	Typical spinal nerve	<p>Define a spinal nerve.</p> <p>Recognize the spinal nerve as a part of PNS.</p> <p>Enumerate the spinal nerves in different regions</p> <p>Identify their location and site of emergence.</p> <p>Identify various components of a typical spinal nerve.</p> <p>Recall the fate of rami.</p> <p>Associate the rami communicans with typical spinal nerve</p> <p>Recall the distribution of gray rami</p>
2	Vertebral column	<p>Describe the muscles of back (origin, insertion, nerve supply, blood supply, and action)</p> <p>Describe Surface anatomy of important muscles</p> <p>Identify structures on CT/MRI of vertebral column taken at various levels</p> <p>Describe clinical anatomy of important muscles</p>
3	Lumbo sacral plexus, cutaneous nerves	<p>Describe the formation of lumbar Plexus.</p> <p>List the branches of lumbar plexus with their root values.</p> <p>Describe relation of the nerves with Psoas major muscle.</p> <p>List the structures supplied by lumbar plexus.</p> <p>Describe the formation of sacral plexus.</p>

		Describe the composition and relations of sacral plexus. List the branches of this plexus
<b>Biochemistry</b>		
4	Phosphorus and Magnesium in biology	Discuss RDA, serum Levels Enlist sources of Phosphorus and Magnesium Describe functions Discuss absorption excretion, Describe disorders related to increase and decrease in amount of Phosphorus and Magnesium
5	Sulphur in biology	Discuss RDA, serum Levels Enlist sources of Sulphur Describe functions Discuss absorption excretion, Describe disorders related to increase and decrease in amount of sulphur
6	Copper and cobalt in biology	Discuss RDA, serum Levels Copper and cobalt Enlist sources of Describe functions Discuss absorption excretion, Describe disorders related to increase and decrease in amount of Copper and cobalt
<b>Community Medicine</b>		
7	Back pain	Explain the causes of low back pain z Describe the prevention of low back pain z Describe the causes & prevention of msd related to child labor



# **Musculoskeletal MODULE**

## **THEME -VI**

**Muscle weakness and fatigue**

SNO	Topic	Learning Outcome
<b>Physiology</b>		
1	Physiologic anatomy of the skeletal muscle fiber	<p>Explain the physiologic anatomy of the skeletal muscle fiber.</p> <p>Skeletal muscle fiber</p> <p>Sarcolemma</p> <p>Myofibrils</p> <p>I band</p> <p>A band</p> <p>Z disk</p> <p>M line</p> <p>Sarcomere</p> <p>Titin microfilament molecules</p> <p>Sarcoplasm</p> <p>Sarcolemmic reticulum</p>
2	Characteristics of whole muscle contraction	<p>Identify the characteristics of whole muscle contraction.</p> <p>Compare isotonic and isometric exercises.</p> <p>Compare and contrast slow and fast muscle fibers.</p> <p>Describe the mechanics of skeletal muscle contraction.</p> <p>Describe muscle tone and muscle fatigue.</p> <p>Describe lever systems of the body and positioning of a body part.</p> <p>Describe remodeling of muscle to match function.</p>
3	Neuromuscular junction	<p>Describe the transmission of impulses from nerve endings to skeletal muscle fibers.</p> <p>Explain the physiologic anatomy of the neuromuscular junction</p>



4	Neuromuscular Transmission	<p>Explain the mechanism of transmission of impulses from nerve endings to muscle fibers</p> <p>Explain Formation and Secretion of acetylcholine at nerve terminals</p> <p>Describe Action of acetylcholine at postsynaptic membrane</p> <p>Describe Degradation/Destruction of released acetylcholine</p> <p>Describe End plate potential</p> <p>Describe Fatigue of junction</p>
5	Neuromuscular drugs	<p>Describe the physiologic basis of the drugs used in the neuromuscular disorders (Drugs that enhance or block the transmission at neuromuscular junction)</p> <p>Enlist the excitatory and inhibitory transmitter substances secreted at the smooth muscle neuromuscular junction</p> <p>Drugs that stimulate the muscle fiber by acetylcholine like action</p> <p>Drugs that stimulate neuromuscular junction by inactivating acetylcholinesterase</p> <p>Drugs that block transmission at the neuromuscular junction</p> <p>Enlist the excitatory and inhibitory transmitter substances secreted at the smooth muscle neuromuscular junction</p>
6	Myasthenia gravis	Describe the pathophysiology of myasthenia gravis
7	Smooth muscle	<p>Classify smooth muscles</p> <p>Describe the physiologic anatomy of the smooth muscle neuromuscular junction</p>
8	Skeletal Muscle fiber	Discuss in detail types of muscles and arrangement of skeletal muscle fibers.

9	Contraction of smooth muscle	<p>Describe the contractile mechanisms in smooth muscles</p> <p>Describe excitation and contraction of smooth muscle.</p> <p>Identify the types of smooth muscles.</p> <p>Describe the chemical and physical basis for smooth muscle contraction.</p> <p>Compare smooth and skeletal muscle contraction.</p> <p>Chemical basis of smooth muscle contraction</p> <p>Physical basis of smooth muscle contraction</p> <p>Explain how the calcium ions regulate the contraction.</p> <p>Regulation of smooth muscle contraction by the calcium ions</p> <p>Enlist the excitatory and inhibitory transmitter substances secreted at the smooth muscle neuromuscular junction</p>
10	Nervous and hormonal control of smooth muscle contraction	<p>Describe the nervous and hormonal control of smooth muscle contraction</p>
11	Resting Membrane Potential	<p>Enumerate the intracellular and extracellular concentrations of sodium, potassium, chloride and calcium ions in a resting/normal cell.</p> <p>Describe the characteristics of major membrane ion channels and their role in the membrane potential</p> <p>Describe the resting membrane potential in a cell/nerve fiber</p>
12	Muscle Remodeling	<p>Describe following</p> <p>Muscle hypertrophy</p> <p>Muscle atrophy</p> <p>Muscle hyperplasia</p> <p>Rigor mortis</p> <p>Muscle dystrophy</p> <p>Recovery of muscle contraction in poliomyelitis</p>

13	Membrane potentials and action potentials in smooth muscles	<p>Describe the membrane potentials and action potentials in smooth muscles.</p> <p>Describe Spike potentials</p> <p>Describe Action potentials with plateaus</p> <p>Describe Role of calcium channels in generating the smooth muscle action potential</p> <p>Describe Slow wave potentials</p> <p>Describe Excitation of visceral smooth muscle by muscle stretch</p> <p>Describe Depolarization of multi-unit smooth muscle without action potentials</p>
14	Control of smooth muscle contraction	Describe the mechanism nervous, hormonal and local control of smooth muscle contraction.
15	Smooth muscle and skeletal muscle contraction	Compare the smooth muscle contraction and skeletal muscle contraction
16	Skeletal muscle contraction	<p>Describe the three sources of energy for muscle contraction</p> <p>Compare isometric and isotonic contractions</p> <p>Compare characteristics of fast and slow muscle fibers.</p> <p>Sources of energy for muscle contraction</p> <p>Compare isometric and isotonic contractions</p> <p>Compare characteristics of fast and slow muscle fibers</p>
Biochemistry		
17	Hormonal regulation	Explain the hormonal regulation of calcium and phosphorous to maintain musculoskeletal system
18	Sodium, potassium and chlorine in biology	<p>Discuss RDA, serum Levels</p> <p>Enlist sources of Sodium, Potassium and chlorine,</p> <p>Describe functions</p> <p>Discuss absorption excretion,</p> <p>Describe disorders related to increase and decrease in amount of Sodium, Potassium and chlorine</p>

19	Calcium in Biology	<p>Discuss RDA, serum Levels</p> <p>Enlist sources of Calcium</p> <p>Describe functions</p> <p>Discuss absorption excretion,</p> <p>Describe disorders related to increase and decrease in amount of Calcium</p>
20	Fluoride and Lithium in biology	<p>Discuss RDA, serum Levels Fluoride</p> <p>Enlist sources of</p> <p>Describe functions</p> <p>Discuss absorption excretion,</p> <p>Describe disorders related to increase and decrease in amount of Fluoride</p> <p>Brief description on role of lithium in biology</p>
21	Molybdenum, Selenium, Zinc, chromium, manganese, silicon, vanadium in biology	<p>Enlist sources of</p> <p>Describe functions</p> <p>Discuss absorption excretion,</p> <p>Describe disorders related to increase and decrease of the said elements</p>
22	Toxic element Aluminum, Arsenic, Antimony, Boron, Bromine, Cadmium, Cesium, Germanium, Lead, Mercury, Silver, Strontium	<p>Discuss different effects of toxic elements</p>
<b>Pharmacology</b>		
23	Drug used in MSK	<p>Define &amp; classify NSAIDS</p> <p>Classify neuromuscular blocking agents.</p> <p>Enlist more most commonly used analgesia aspirin, ibuprofen, diclofenac, paracetamol, COX-2 Salicox</p> <p>Classify corticosteroids</p>

Community Medicine		
24	MSK diseases	<p>Explain the risk factors for different types of msd's</p> <p>Describe the preventive measures for different types of risk factors for msd's</p>
25	Epidemiology and prevention of MSD	<p>Describe work related msd's</p> <p>Identify risk factors of msd at workplace.</p> <p>Describe prevention of exposure to risk factors related to workplace.</p> <p>Describe the preventive strategies and safety guidelines in order to reduce the incidence of msds related to work place.</p> <p>Describe the burden /epidemiology of work related msd's</p> <p>Describe application of ergonomics in the prevention of work related msd's</p>